RECONSTRUCTION OF SOFT TISSUE AND BONE DEFECTS IN LOWER EXTREMITY WITH FREE FLAPS

IBRAHIM KAPLAN, M.D.,* SAIT ADA, M.D.,
FUAT ÖZERKAN, M.D., ARSLAN BORA, M.D., and
YALÇIN ADEMOGLU, M.D.

This article reports our experiences treating soft tissue and bone defects in the lower extremity with free flaps. One of the most common causes for lower extremity wounds are high-energy injuries. These kinds of injuries contain soft tissue and bone defects beyond neurovascular complications. The rate of infection and nonunion is very high in these injuries. Between 1988 and 1996, we applied 33 flaps to 28 patients. The numbers and kinds of the free flaps are as follows: 12 latissimus dorsi, nine radial forearm, seven lateral arm, three vascularised fibula grafts with skin, one gracilis, and one medial plantar flap. Three free flaps were lost (12%). The success rate is 88%. The advantage of free flaps is that they allow the reconstruction of the large defects in one-session operations. Thus, they decrease the rate of infection and increase that of nonunion. The patient returns to his active life at an earlier stage.

MICROSURGERY 18:176–181 1998

Complex lower extremity injuries are common problems, and they frequently affect the young. Both limbs may be involved compounding the reconstructive problem. In some patients, amputation has been the only solution when skin and musculoskeletal loss has been extensive. The combined use of early thorough wound debridement, appropriate antibiotic coverage, and wound closure with free flaps provide a potential solution to the problem of these complex injuries.

MATERIALS AND METHOD

Between 1988 and 1996, we applied 33 free flaps to 28 patients with isolated soft-tissue defects, or soft tissue defects together with bone defects in lower extremity. Five patients were female and 23 were male. The age range was 8–55, the mean age being 27. The tissue defect was on the left in 16 patients, the right in 10, and bilateral in two.

The cause of injury was a road traffic accident in 21, work accident in four, firearm injury in one, crush under a heavy-weight object in one, and sports injury in one. Twelve patients had a bone defect accompanying a soft-tissue defect and 16 had only a soft-tissue defect. According to Gustillo's classification, there were type 3B open fractures in 10 patients, and type 3C in two patients. For both of the patients who had open fracture type 3C, the restoration of circulation was achieved by means of a saphenous vein graft.[1]

Twelve latissimus dorsi, nine radial forearm, three vascularised fibular grafts with skin, seven lateral arm, one gracilis, and one medial plantar flap were applied as free flaps. Free flaps were carried out at the acute stage of the injury (the first 5 days) in six patients, at the sub-acute stage (1–6 weeks) in 17 patients, and at the chronic stage (after 6 weeks) in five patients, out of 28.[2] For the reconstruction of foot and heel, three latissimus dorsi without skin, seven radial forearm, five lateral arm, and one medial plantar flap were applied.

In our patients, we employed radical debridement, antibiotic therapy, fracture stabilisation, and early soft tissue reconstruction with free flap for definitive wound management.

RESULTS

In six of the 33 free flaps we applied, problems of circulation occurred at the postoperative early stage (18.3%). All of them were re-explored. Two flaps were saved, however the other four were lost (12%). The success rate was 88%. One of the lost flaps was the lateral arm flap placed on the dorsal of the foot for skin defect. Due to necrosis, we performed debridement. After the formation of granulation tissue a split-thickness skin graft was applied. Another lost flap was the latissimus dorsi flap applied to the dorsal of the foot for metatarsal defect and soft tissue defect. After debridement a contralateral latissimus dorsi flap was applied. The vascularised fibular graft with skin, applied to the left

Hand and Microsurgery Hospital, Kahramanlar, Izmir, Turkey

*Correspondence to: Dr. Ibrahim Kaplan, El ve Mikrocerrahi Hastanesi, 1418 Sokak, No. 14, 35230 Kahramanlar, Izmir, Turkey.

Figure 1. 24-year-old male patient. He had type 3C open fractures of his left lower leg. The soft tissue defect was 22 x 10 cm and bone defect was 16 cm.

lower limb of the patient with skin and bone defect, was the fourth one lost. Since the circulation in the foot deteriorated after the debridement, a below-the-knee amputation was performed.

For reconstruction of the foot and heel, latissimus dorsi flaps without skin were applied to three patients, radial forearm flaps to seven patients, lateral arm flaps to five patients, and medial plantar flap to one patient. Primary healing occurred in 16 patients. In the follow-up there were no problems of wound or instability of the flap.

Vascularised fibular flaps were applied to three patients, latissimus dorsi muscle flaps to six patients, gracilis muscle flap to one patient, and radial forearm flaps to two patients who had open fracture type 3B (10 patients) and open fracture type 3C (two patients) according to Gustillo's classification. In one patient with a bone defect, lengthening was carried out by means of Ilizarov after the free muscle flap (Table 1: Case no. 7). Osteomyelitis was not observed in any of the patients. Nonunion was seen in two patients. Corticospongious bone grafts had been applied to both of these patients during the muscle flap.

In two patients to whom vascularized fibular grafts were applied, first, fixation by means of external fixator until union occurred, and then a functional brace in order to protect the fibula, were applied. The fibula was fractured in one patient. However, it was healed by splinting without causing any problems.

It was determined that the patients' stay in hospital ranged from 1 week (minimum) to 6 weeks (maximum), the average being 3 weeks. The patients underwent a minimum of one operation and a maximum of seven operations, including debridement and skin grafting. The average number of operations was two.

We started weightbearing after primary wound healing in patients with reconstruction of the foot soft tissue and after union in patients with fracture and vascularised fibular graft. The earliest weightbearing time was 4 weeks and latest was 14 weeks. The average was 12 weeks. The follow-up was 6 weeks minimum, 82 months maximum, the average being 20 months.

DISCUSSION

Lower extremity injuries, especially open fractures of Gustillo type 3B and type 3C, are caused by high-energy trauma and contain neurovascular problems accompanying



Figure 2. We used vascularised fibular graft with skin. An Orthofix external fixator was used for fixation.

bone and soft tissue defects.[1–5] Open fractures, such as Gustillo type 3B and type 3C, require free flaps for treatment and have a great number of complications.

The factors which effect the result in these types of injuries can be listed as follows:

1. Radical debridement
2. Rigid fixation
3. Two or more debridement procedures, if necessary
4. Antibiotics
5. Closing the defect of free-muscle flap
6. Application of corticospongious grafts for the bone defects smaller than 6 cm, and vascularised bone grafts for the ones larger than 6 cm, after the healing of the soft tissue.[1–5]

Closing open fractures with free muscle flaps both prevents infection and has a positive effect on bone healing related to the increase in vascularity.[1,3,6–9] In our series, we applied eight free latissimus dorsi flaps and one gracilis flap to eight open fractures type 3B and one open fracture type 3C with soft tissue defect. Osteomyelitis was not observed in any patient. The most important factor, which effects the result in a positive way is closing the open fractures with free muscle flaps before the formation of bacteria colonization.[2–4,9,10]

Covering the wound with free tissue at the acute phase, the first 5 days according to Byrd et al.,[2] the first 3 days according to Godina,[4] and the first 17 days according to Yaremchuk et al.,[9] significantly decreases the rate of complications compared to the subacute phase. The subacute phase is the period of the first 6 weeks according to Byrd et al., and the first 3 months according to Godina. For instance, the rate of complication recorded at the acute phases ranges between 19 and 0.75%, and 60 and 12% at the subacute phase according to the authors, respectively. Therefore, free flap application should be avoided at the subacute phase of the injury.

Open fractures of Gustillo type 3B and type 3C are the ones which co-exist with bone defect or whose vascularity has deteriorated. That is why they require corticospongious bone graft or vascularised bone graft in accordance with the size of the defect in order to achieve union.[1–3,9] To reduce the risk of infection or to achieve the optimum level of local vascularity necessary for union it is essential that the defect must be closed with free muscle flap first, and bone graft must be applied 4–6 weeks later.[2,3,5,7,9] In our series, in two

Table 1. Reconstruction of Soft Tissue and Bone Defects in Lower Extremity With Free Flaps

Case		Age	Sex	Side R.	Side L.	Side Bil	Causes	Time in hospital	Bone or soft tissue defect	Defect size	Location of defect
1	O.B.	24	F		+		Traffic accident	1 Week	Soft tissue defect and Type 3B open fracture	7 × 10 cm	Right heel + right cruris 1/3 proximal
2	H.Y.	19	M		+		Work accident	3 Weeks	Soft tissue defect	6 × 12 cm	Right dorsum of foot
3	A.A.	23	M		+		Firearm injury	2 Weeks	Neurovascular injury and soft tissue defect	6 × 13 cm	Right heel
4	N.A.	25	F	+			Traffic accident	6 Weeks	Left type 3C open fracture Right type 2 open fracture	Left 15 × 25 cm	Left cruris anterior
5	R.E.	30	F	+			Traffic accident	4 Weeks	Type 3B open fracture	11 × 15 cm	Left dorsum of foot
6	A.C.	28	M			+	Traffic accident	6 Weeks	Bil. type 3B open fracture	Right 15 × 28 cm Left 14 × 26 cm	Bil. cruris
7	H.P.	10	M			+	Traffic accident	6 Weeks	Bil. type 3B open fracture	Left 10 × 22 cm Right 12 × 24 cm + 10 cm Bone Defekti	Bil. cruris
8	H.I.	19	M	+			Traffic accident	3 Weeks	Left type 3B open fracture	20 × 30 cm	Left front of foot
9	G.O.	39	M	+			Traffic accident	5 Weeks	Left below knee amputation stump	14 × 25 cm	Left below knee
10	A.S.	25	M	+			Traffic accident	2 Weeks	Type 3B open fracture	8 × 14 cm	Left cruris anterior
11	L.G.	25	M	+			Traffic accident	3 Weeks	Soft tissue defect	12 × 22 cm	Left foot plantar side
12	E.E.	24	F	+			Press injury	2 Weeks	Soft tissue defect	10 × 20 cm	Front of foot
13	M.B.	55	M		+		Traffic accident	3 Weeks	Soft tissue defect	10 × 16 cm	Right heel
14	M.A.	14	M	+			Traffic accident	2 Weeks	Soft tissue defect	11 × 22 cm	Left front of foot
15	O.K.	8	M		+		Traffic accident	2 Weeks	Right knee flex contracture	10 × 16 cm	Posterior of right knee
16	R.A.	38	M		+		Traffic accident	4 Weeks	Soft tissue defect	10 × 18 cm	Right heel
17	S.O.	8	M	+			Traffic accident	6 Weeks	Type 3B open fracture	Skin 10 × 18 cm Bone 14 cm	Left cruris
18	B.K.	24	M	+			Traffic accident	4 Weeks	Type 3C open fracture	Skin 22 × 10 cm Bone 16 cm	Left cruris
19	A.A.	24	M	+			Traffic accident	2 Weeks	Type 3B open fracture	Skin 22 × 14 cm Bone 15 cm	Left cruris
20	T.C.	45	M		+		Work accident	3 Weeks	Soft tissue defect	13 × 6 cm	Right front of foot
21	R.G.	21	M	+			Traffic accident	1 Week	Osteomyelitis and soft tissue defect	16 × 7 cm	Left cruris anterior
22	F.S.	41	F	+			Work accident	2 Weeks	Soft tissue defect	17 × 7 cm	Left ankle
23	S.A.	23	M		+		Work accident	4 Weeks	Soft tissue defect	10 × 8 cm	Plantar side of heel
24	M.P.	29	M		+		Traffic accident	2 Weeks	Soft tissue defect	11 × 5 cm	Right dorsum of foot
25	F.K.	31	M	+			Sport injury	2 Weeks	Soft tissue defect	15 × 7 cm	Left heel
26	A.G.	27	M		+		Traffic accident	4 Weeks	Soft tissue defect	12 × 6 cm	Right cruris anterior
27	E.T.	38	M	+			Traffic accident	4 Weeks	Soft tissue defect	17 × 10 cm	Dorsum of foot
28	H.T.	41	M	+			Traffic accident	1 Week	Soft tissue defect	10 × 8 cm	Left ankle

Continued

Table 1. Reconstruction of Soft Tissue and Bone Defects in Lower Extremity With Free Flaps (*Continued*)

Time injury to flap	Flap	Number of operation	Fixation device	Time flap to bone graft	Time to weight bearing	Early complications	Late complications
90 Days	Right lateral arm + gracilis	2	Plate and screw	—	4 Weeks	—	—
30 Days	Left lateral arm	3	—	—	8 Weeks	Flap necrosis	—
Emergency	Left lateral arm	1	—	—	7 Weeks	—	—
7 Days	Latissimus dorsi	4	Orthofix	Same session	25 Weeks	—	Nonunion
14 Days	Latissimus dorsi	4	K-Wire	Same session	12 Weeks	Flap necrosis	—
Right 21 Days, left 28 Days	Bil. lattissimus dorsi	6	Orthofix	—	72 Hafta	—	—
Right 18 Days, left 6 Days	Bil. latissimus dorsi	7	External Fiksatör	Lengthening with İlizarov technique	Left 12 Weeks	—	—
4 Days	Latissimus dorsi	3	—	—	12 Weeks	Vein thrombosis and reexploration—Saved	—
14 Days	Latissimus dorsi	1	—	—	8 Weeks	—	—
35 Days	Latissimus dorsi	1	Orthofix	Same seesion	12 Weeks	—	Nonunion
3 Days	Left radial forearm	2	—	—	8 Weeks	—	—
21 Days	Left radial forearm	1	—	—	6 Weeks	—	—
21 Days	Left radial forearm	1	—	—	8 Weeks	—	—
14 Days	Left radial forearm	1	—	—	12 Weeks	—	—
112 Days	Latissimus dorsi	1	—	—	4 Weeks	—	—
84 Days	Latissimus dorsi	1	—	—	6 Weeks	—	—
28 Days	Vascularised fibular graft with skin	4	Screw	—	Amputation	Flap necrosis	—
84 Days	Vascularised fibular graft with skin	4	Orthofix	—	24 Weeks	—	—
252 Days	Vascularised fibular graft with skin	2	Orthofix	—	16 Weeks	—	—
10 Days	Radial forearm	3	K-Wire	Same session	16 Weeks	Vein thrombosis and reexploration—Saved	—
30 Days	Radial forearm	1	—	—	3 Weeks	—	—
Emergency	Radial forearm	4	K-Wire + Malleolar Screw	—	16 Weeks	—	—
15 Days	Medial plantar flap	3	K-Wire	—	12 Weeks	—	—
20 Days	Lateral arm	1	K-Wire	—	4 Weeks	—	—
20 Days	Lateral arm	1	—	—	4 Weeks	—	—
14 Days	Lateral arm	3	External Orthofix	—	20 Weeks	—	—
17 Days	Radial forearm + lateral arm	6	Ender Nail	—	8 Weeks	Flap necrosis	—
Emergency	Radial forearm	1	—	—	4 Weeks	—	—

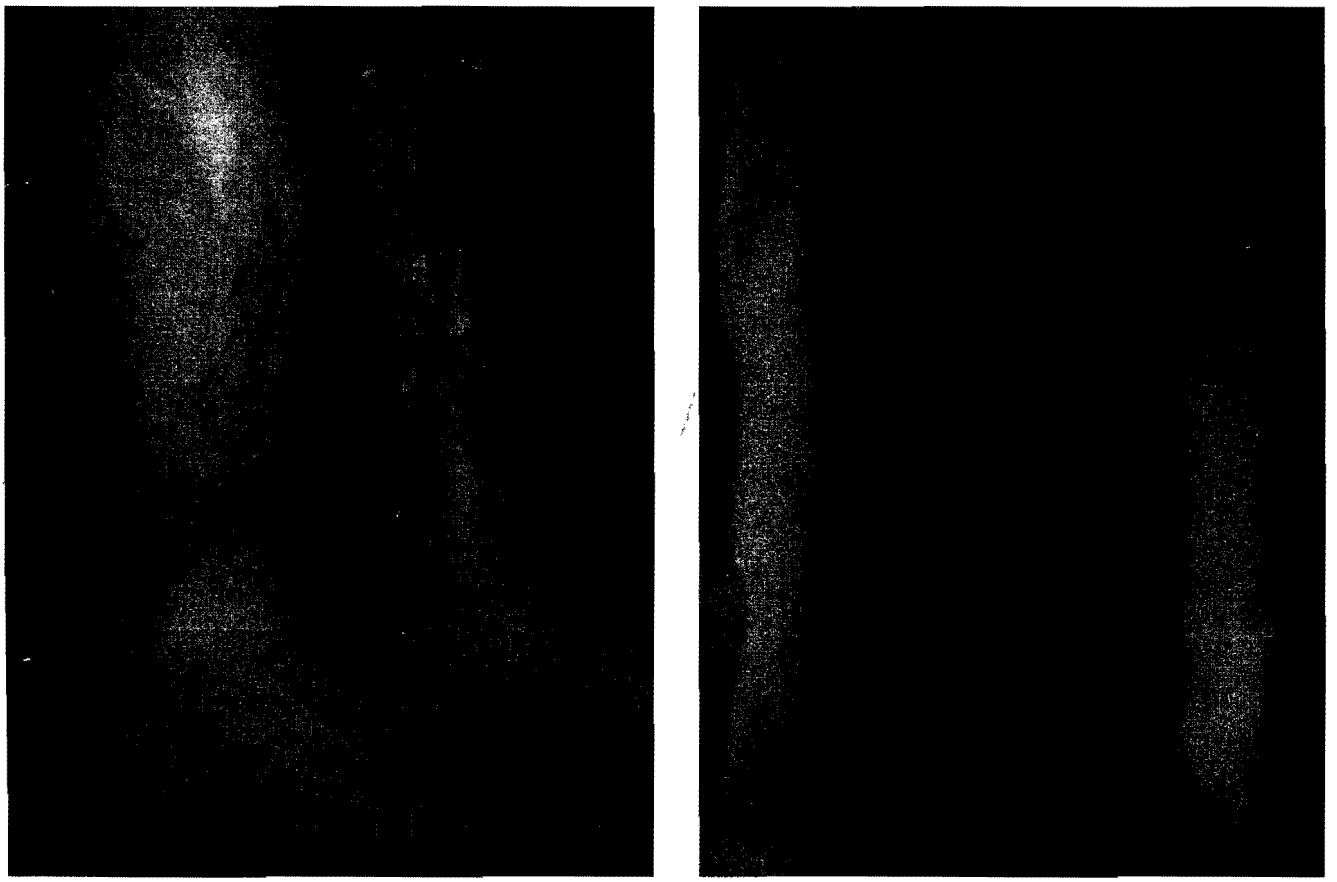

Figure 3. Functional results after 30 months.

patients where nonunion was observed, bone graft and free muscle flap were applied in the same session. We are of the opinion that the later application of the bone graft will effect the success to be achieved in a positive way. In cases where the bone defect is larger than 6 cm, a vascularised bone graft is needed.[5,7,9] In our series, we applied vascularised fibular grafts with skin to three patients.

We applied 16 free flaps for the reconstruction of foot and heel. No problem of ulcers or instability was observed in any of the flaps.[11] The average hospital stay was 3 weeks and the average number of operations was two, indicating the efficacy of treating these types of complex injuries with free-flaps.[4,7,8]

CONCLUSION

For the common problem of lower limb injury with extensive loss of skin and bone, free flaps have been used successfully with radical debridement, rigid bone fixation, and appropriate IV antibiotics.

REFERENCES

1. Gustillo RB: Open fractures. Gustillo RB, Kyle RF, and Templeman D: *Fractures and Dislocations.* Vol. 1. St. Louis, Mosby, 1993.
2. Byrd HS, Spicer TE, Cierney G: Management of open tibial fractures. *Plastic Reconstruct Surg* 76:719–728, 1985.
3. Francel TJ, Kolk CAV, Hoopes JE, Mauson PN, Yaremchuk MJ: Microvascular soft tissue transplantation for reconstruction of acute open tibial fractures: Timing of coverage and long-term functional results. *Plastic Reconstruct Surg* 89:478–486, 1992.
4. Godina M: Early microsurgical reconstruction of complex trauma of the extremities. *Plastic Reconstruct Surg* 78:285–292, 1986.
5. Gorman PW, Barnes L, Fischer TJ, McAndrew MP, Moore MM: Soft tissue reconstruction in severe lower extremity trauma. *Clin Ortho Related Res* 243:57–64, 1989.
6. Fisher J, Wood MB: Experimental comparison of bone revascularization by musculocutaneous and cutaneous flaps. *Plastic Reconstruct Surg* 79:81–89, 1987.
7. Swartz WM, Mears DC: The role of free-transfer in lower extremity reconstruction. *Plastic Reconstruct Surg* 76:364–373, 1985.
8. Weiland AJ, Moore JR, Daniel RK: The efficacy of free transfer in the treatment of osteomyelitis. *J Bone Joint Surg* 66A:181–193, 1984.
9. Yaremchuk MJ, Brumback RJ, Mauson PN, Burgess AR, Poka A, Weiland AJ: Acute and definitive management of traumatic osteocutaneous defects of the lower extremity. *Plastic Reconstruct Surg* 80: 1–12, 1987.
10. Chen SHT, Wei F-C: Emergency free flap transfer for reconstruction of acute complex extremity wounds. *Plastic Reconstruct Surg* 89:882–888, 1992.
11. Ferreire MC, Besteiro JM, Monteiro AA, Zumiotti A: Reconstruction of the foot with microvascular free flaps. *Microsurgery* 15:33–36, 1994.