FREE FLAPS WE USED IN ORTHOPAEDIC RECONSTRUCTION

İbrahim KAPLAN*, Sait ADA*, Fuat ÖZERKAN*, Arslan BORA* Gülin ARIKAN**
* İzmir Hand and Microsurgery Hospital, Hand Surgeon.
* İzmir Hand and Microsurgery Hospital, Physiotherapist.

Abstract

Between the years 1988-1993, 55 free flaps were applied to 46 patients at the İzmir Hand and microsurgery Hospital. 4 of the flaps failed due to blood circulation problem. The percentage of success is 92.7%. Reexploration was made on 7 patients and 12.7% success was attained. 3of the 7 reexplored flaps were saved. Our opinion is that, the two most important facts effecting the success to be achieved in Flap Surgery are meticulous anastomose and close clinical follow up in the first 3 days of the post operative period.

Key Words: Reconstrictive Microsurgery, Free Flaps.

INTRODUCTION:

After the application of the first free flap operation by Gilowy, Lamb and White in 1972, the level Reconstructive microsurgery reached recently, provided solutions for the loss of skin, tendon, bone, vein and nerves due to injuries or for other reasons with one stage operations. In this kind of one stage flap operations, all the lacking tissues can be transferred to the defected zone on one vascular pedicule, together with nerve, bone and tendon grafting in the same session (1,3, 4, 14). Therefore the period to be an in-patient and to determine the extremity shortens, providing possibility for early physiotherapy.

Material and Method

In the 6 year period between 1988-1993, 55 flaps were applied on 46 patient. 3 of the patients were female and 43 of them were male. The youngest patient was 5, the oldest patient was 67 years old, with an average age of 25.5 years. 4 flaps were applied on one patient and two free flaps were applied on each of the six patients (Table 1). The reason of the injuries were determined as 12 traffic accidents, 20 occupational accidents, 5 gun injuries, 2 burns, 2 belt injuries, 1 osteomyelitis, 1 elevator accident, 1 glass cut, 1 sports injury and 1 injury with unknown reason (Table 1).

Of the 55 free flaps, 11 were latissimus dorsi, 12 were lateral arm, 9 were radial forearm flap, 4 were free vascularised fibula, 5 were joint transfer, 3 were transfer of toe to hand, 2 were dorsalis pedis, 1 was iliac wing scapular, 1 was Gracilis flap and one was posterior interosseous artery flap (Table 2)

The operation period was at most 11, at least 5 hours, with an average of 7 hours. grafts. We used 500 cc/day of Rheomakrodex, double antibiotic, 500 mg/day of Aspirin and 15-20.000 units of Heparin-if required- in the postoperative 5 day period. Flap circulation follow-up was done by clinical temperature, colour and bleeding controls. The vitality of the flap was followed by synthigraphy if nonskin vascularized bone graft was applied. Synthgraphy was carried out on the postoperative 4th day. The average period of being in-patient was determined as 7 days and the average hot ischemy period of the taken flaps were determined as 1.5 hours. Free flaps were applied on 14 patients (30%). Urgently and on 32 (70%) patients under elective conditions.

Results

Circulation problem occured in 7 flaps in the postoperative period. All of them were reexplored. Venose trombus was observed on 3 flaps. The flaps were saved from loss after reanastomose in these 3 patients. But artery and venouse trombus were found on the other four patients. These four flaps failed although reanastomose was done. The defects after the failure of one latissimus dorsi and one radial artery flap were covered with flaps that were retaken from the donor. Skin grafting was done after dressing in the defected zone for the failed one lateral arm flap and one venouse flap. One problem after skin grafting occured in the donor zone of a patient from whom a dorsalis pedis flap and a lateral arm flap

TABLE I

AGE	SEX	TYPE OF INJURY	SITE OF THE DEFECT	TYPE OF THE FLAB AND SECONDARY OPERATION
30	F	Traffic Accident	Left food dorsum	Bilateral Lat. Dorsi Flap + Bone Graft
8	M	Traffic Accident	Flexion contracture of right knee and defect of the N.Perenous com.	Righ Lat. Dorsi Flap + Nerve Graft
25	M	Traffic Accident	Open fracture of left cruris	Left Lat. Dorsi Flap + Bone Graft
33	M	Traffic Accident	Left Cruris amputation stump	Left Lat. Dorsi Flap
38	M	Sensory Loss	Open wound of the right heel	Left Lat. Dorsi Flap
28	M	Traffic Accident	Bil.cruris 3.degree open fracture	Bil. Lat. Dorsi Flap
7	M	Elevator Injuries	Left forearm crush injuries	Functional Right Lat. Dorsi Flap for Ext.defect
10	M	Traffic Accident	Bil.Cruris subtotal amputation	Bil. Lat. Dorsi flaps
15	M	Press Injuries	Left hand crush injuries	Right Dorsalis Pedis Flap,Free Vascularized Joint transfer
30	M	Traffic Accident	Dorsum at the left hand crush injuries	Left Dorsalis Pedis Flap
24	M	Traffic Accident	Right cruris and heel open wound	Left Gracilis and left Lateral Arm Flap
25	M	Machine Injury	Dorsum of the 2.and 3. fingers of the left hand	Left Lateral Arm Flap
47	M	Gun shut injuries	Left hand dorsum	Left Lateral Arm Flap
30	M	Press Injuries	Left hand 3.,4. and 5. fingers subtotal amp.	Left Lateral Arm Flap
23	M	Press Injuries	2. and 3. fingers of the right hand degloving injuries	Right Lateral Arm Flap
12	M	Press Injuries	Crush injuries of the right hand	Right Lateral Arm Flap
19	M	Rolling Belt Injuries	Open wound of the right food dorsum	Left Lateral Arm Flap
25	M	Machine Injuries	Skin defect of the left hand dorsum (2.,3. and 4. fingers)	Left Lateral Arm Flap
23	M	Press Injuries	Skin defect of the right hand palmar side	Right Lateral Arm Flap
19	M	Burn Contracture	Left hand	Left Lateral Arm Flap
38	M	Press Injuries	Left hand skin defect	Left Lateral Arm Flebi
22	M	High voltage Inj.	Right wrist	Right Lateral Arm Flap
24	M	Crush Injury	Dorsum of the right food	Left Radial Arter Flap
45	M	Machine Injury	Open wound of left heel	Left Radial Arter Flap
14	M	Traffic Accident	Amputation of the right forefood	Right Radial Arter Flap
9	M	Traffic Accident	Subtotal amputation of the right arm	Left Radial Arter Flap
67	M	Gun shut Injuries	Skin defect of the palmar side of the left hand	Right Radial Arter Flap
18	M	Machine Injuries	Two segmentary amputation of left forearm	Right Radial Arter Flap
35	M	Crush Injuries	Dorsum of the left forearm soft tissue defect	Right Radial Arter Flap with Vasc.Tendon Graft
22	M	Sport Injuries	Skin defect of the right heel	Left Radial Artery Flap with Vasc.Tendon Graft
55	M	Machine Injuries	Left hand palmar side skin defect	Skapular flap
22	M	Press Injuries	Right hand 3. and 4.fingers subtotal amp.	Venous flap for the 3.finger
31	M	Machine Injuries	Right hand 4.finger	Venous Flap
5	M	Rolling Belt Injuries	Right hand 3. and 4. fingers volar side skin defect	Venous flap for the 4.finger
40	M	Gun Shut Injuries	Skin defect of the right hand dorsum	Right Mc Gregor Free Flap
28	M	Machine Injuries	Degloving Injuries of the left forearm	Left Mc Gregor Free Flap
28	M	Clean Injuries	Flexion contracture of the right wrist	Right posterior interosseous artery flap
28	M	Traffic Accident	Left cruris subtotal amp.	Right vascularized fibula graft with skin
25	M	Gun shut injuries	Pseudoartrozis of the left humerus	Left vascularized fibula graft with skin
21	M	Osteomyelitis	Left tibia pseudoarthrozis	Right vascularized fibula graft
31	M	Gun shut injuries	Right radius pseudoarthrozis	Left vascularized fibula graft
36	M	Traffic Accident	Bone and skin defect dorsum of the left hand	Vascularized iliac Bone graft with skin
31	M	Machine Injuries	Right hand 2.and 3. finger injuries	Vascularized joint transfer 2.->3.
17	M	Machine Injuries	Left hand 2.finger PIP injuries	Vascularized joint transfer from toe
22	M	Machine Injuries	2. and 3. fingers amp. from right hand	2. and 3. toes transfer
13	M	Press Injuries	Left thumb amp.	Right 2.toe->thumb transfer

of more than 7 cm in width were taken. However, the problems were solved with wound treatment before a surgical intiative was required. Fracture occured in the postoperative follow-up period of 2 patients on whom vascularized fibula transfer was made due to tibia defect. Fracture healing was provided with plaster treatment.

Discussion

In the recent years, complication after flap applications has reduced due to the development of microsurgical methods and usage of suitable materials. The success percentage of flap operations in literature is between 87-98%. In our series of cases this ratio is 92.8% (3,4,14).

The unity of vascular structure is determinde by Doppler in the preoperative period. Angiography wjas not preffered becuse of the risk of destructing the endotelial structure of the vessels and the high cost of it (1). To remove the wide soft tissue injuries that occur in upper and lower extremity 3rd and 4th grade open fractures and soft tissue defects that appear after bone fixation, vein and nerve repair in infected pseudoartroses or for the reconstruction of the function lacking

TABLE II

FLAP DONORSITES	FLAP NUMBER	SURVIVAL	NECROSIS	CAUSE
LATISIMUS DORSI FLAP				
A- With Skin	6	6	-	-
B- Without skin	4	3	1	Artery and Vein Trombozis
C- Functional	1	1	-	-
LATERAL ARM FLAP	12	11	1	Artery and Vein Trombozis
RADİAL ARTER FLAP				
A- Skin and Fascia	7	6	1	Artery and Vein Trombozis
B- Skin, Fascia and Vascularized Tendon Graft	2	2	-	-
GRACİLİS				
A- With Skin	1	1	-	-
B- Without Skin	-	-	-	-
VENEUS FLAP				
A- Arterialize	3	2	1	-
B- Pure Venous	-	-	-	-
SKAPULAR FLAP	1	1	-	-
FREE MC GREGOR FLAB	2	2	-	-
DCIA FLAP -Skin+Bone	1	1	-	-
VASculanzed FİBULA				
A- With Skin	2	2	-	-
B- Without Skin	2	2	-	-
FREE ASCULARIZED JOINT				
A- Foot	4	4	-	-
B- From nonreplanted finger	1	1	-	-
TOE-TO THUMB	1	1	-	-
POSTERİOR İNTEROSSÖZ ARTERIEL FLAB- Fascial	1	1	-	-
DORSALİS PEDİS	2	2	-	-
TOE TO FINGER	2	2	-	-

muscles, latissimus dorsi muscle with or without skin is one of the first flaps to be elected due to the reliability of the pedicule and the facility to take it in the required length and width (2,7). Wa also applied latissimus dorsi for covering the soft tissue defects in 10 of our cases and for functional muscle transfer in one. Neither wound problem or infection was observed in any of the patients. Vascularised bone grafts can be appliedas with skin with muscle or without skin for bone defects that are 6 cm. or longer, or for situations of insufficient blood circulation in the zone on which conventional bone graft is to be aplied (12, 13, 16). We applied vascularised fibula graft on 2 of our cases with skin and on 2 of our cases without skin. We applied vascularised iliac wing graft together with skin on another patient. Union occured in all of them. We followed the vitality of nonskin vascularised bone grafts with synthygraphy. However we observed that this method was not practical for clinical applications, therefore we claim that application of bone grafts with skin is quite a reliable method for clinical follw-up. Nonunion problem occured in the vascularised fibula grafts applied on lower extremity, but fractures in fibula appeared after loading. As a result, our opinion is that it has to be protected wwith brace in the follow-up period.

The radial artery flap although it creates a cosmetic problem in the donor zone can be selected for soft tis-

sue defects that require vascularised tendon graft, as the diameter of its vessels are sufficient (9, 11).

Radial artery flap is also applied on 2 of our patients with vascularised tendon graft and on 6 of our patients for soft tissue defect. Lateral arm flap is the most commonly applied free flap, because it stays in the same operation zone and creates no problem in covering the small defects less than 7-8 cm on hand or in cases that cause skin problem like achilles tendon rupture, as it creates no problem for donor zone and gives good cosmetic appearance (6). The lateral arm flap was also the most commonly used free flap in our series. The vascularised joint transfer in children and young patients is a treatment method to be considered in small joint injuries on hand together with skin, tendon and bone defects or in multiple joint injuries. Vascularised joint transfer is also applied on 5 joint of our 3 patients (10).

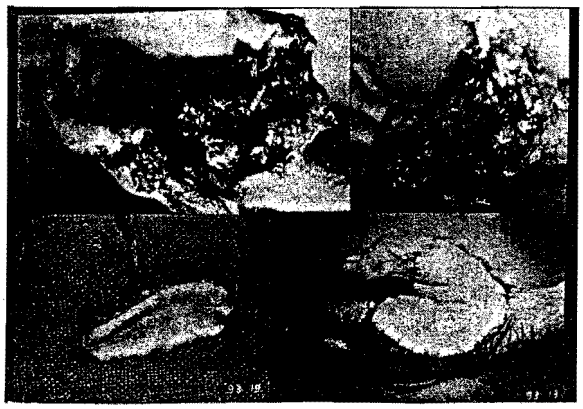

Figure 1 - R.A., age 47, male patient. Gun shut injuries of this left hand.
Revascularization of the thumb and for the soft tissue defect of the dorsum of the hand. We used the lateral Arm Flab.



Figure 2 - K.D., age 21, male patient.
Pseudoartrosis of left tibia. He has 6 cm. shortness.
Lengthning was made with Ilizarove Method and we used vascularize fibula graft.

In multiple finger deficiencies of hand including thumb, one, two or more toes can be used to bring function and aesthetic to the hand (8,15). In one of our cases the second toe is transferred in the place of thumb and in another case 2nd and 3rd toes are transferred in the place of amputated 2rd and 3rd fingers of DIP level. 3 arterialize venose flap has been used because its circulation was more reliable (5).

LITERATURE

1. Bernad MO, Alan MM and Jayne AM. Microvascular Free Flab Transfer Orthopaedic Clinics of North America, 8:349-366, 1977.

2. Byrd HS, Spicer TE, Cierney G. Management of Open Tibial Fractures. Plastic and reconstructive Surgery, 76:719-730, 1985.

3. Cao D and Jang N. The Use of Free Flabs in Burn Patients: Experiences with 70 Flaps in 65 Patients. Plastic and reconstructive Surgery, 81:352-357, 1988.

4. Harashina T. Analysis of 200 Free Flaps. British Journal of Plastic Surgery, 41:33-36, 1988.

5. Katsaros J and Others. The use of the Lateral Arm Flap in Upper Limb Surgery J. hand Surgery, 16-A: 598-604, 1991.

6. Katsaros J and Others. The use of the lateral Arm Flap in Upper Limb Surgery J. Hand Surgery, 16-A: 598-604, 1991.

7. May JW, Gallico GG, Jupiter J, Savage RC. Free Latisimus Dorsi Muscle Flap with Skin Graft for Treatment of Traumatic Chronic Bony Wounds. Plastic and Reconstructive Surgery, 73: 641-649, 1984.

8. Oksuta H, Torigai K and Shioya N. Two toe-to-Finger Transplants in one hand. Plastic and reconstructive Surgery, 60:561-565, 1977.

9. Reid CD, and Moss LH. One-Stage Flap Repair with Vascularised Tendon Grafts in a Dorsal Hand Injury Using the "Chinese" Forearm Flap, British Journal of Plastic Surgery, 36:473-479, 1983.

10. Smith PJ and Goodacre TEE. Free Vascularised Toe Joint Transfer for Reconstruction of the Metacarpophalangeal Joint. Journal of Hand Surg., 15-B: 262-267, 1990.

11. Soutar DS and Tauner NSB. The Radial Forearm Flap in the Management of Soft Tissue Injuries of the Hand. British Journal of Plastic Surg., 37:18-26, 1984.

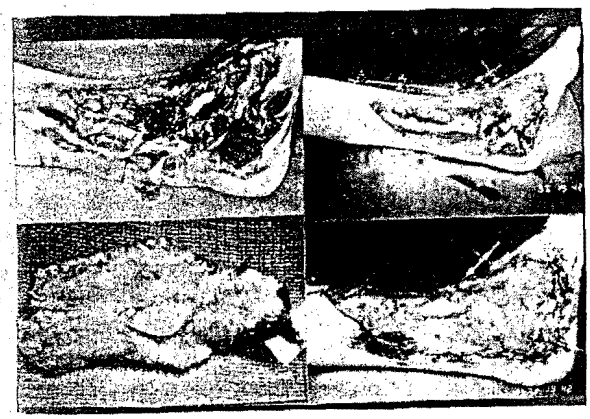

Figure 3 - H.P., age 8, male patient. Bilateral cruris injury (Traffic Accident). We used bilateral Latissimus Dorsi Flaps.

12. Taylor GL, Miller GDH, Ham JF. The Free Vascularized bone Graft. Plastic and Reconstructive Surgery, 55:533-544, 1975.

13. Taylor GL, Towsend P, and Carlett R. Superiority of the Deep Circumflex Iliac Vessels as the Supply for Free Groin Flaps. Plastic and Reconstructive Surgery 64: 595-604, 1979.

14. Raatikainen TK. Fifty consecutive free flaps in a new microsurgical unit. Microsurgery, 15:153-154, 1994.

15. Wei FC, Chen HC, Chuang CC and Hoordhoft MS. Simultaneous Multiple Toe Transfer in Hand Reconstruction. Plastic and Reconstructive Surgery, 81:366-374, 1988.

16. Yoshimura M, Shimamura K, Iwai Y, Yamauchi S, Veno T. Free Vascularized Fibular Transplant. J.B.J.S., 65-A: 1293-1301, 1983.