The development of microsurgery with regard to replantation of severed extremities has in Turkey been a relatively recent although rapid process. The first revascularization was performed by our team in Izmir in 1986. By 1988 a 24-hr emergency replantation service was available and a special surgery branch hospital in hand and microsurgery was established in 1991. This hospital was the first of its kind in Turkey and one of the few in the world. Here we present our replantation series comprising 83 patients treated between July, 1986, and December, 1990. From a total of 83 patients, 136 extremities were involved, with only 24 of 136 lost; a success rate of 82%. Functional results were rated as excellent or good in 49 cases.

MICROSURGERY 14:97–101 1993

REPLANTATIONS AND THEIR FUNCTIONAL RESULTS: THE TURKISH EXPERIENCE

ARSLAN BORA, M.D., SAIT ADA, M.D., FUAT OZERKAN, M.D., and FIRDEVS TETIK, P.T.

In Turkey, the first replantation was performed in Istanbul in 1978.[1] Our team performed the first revascularization in Izmir in 1986, and we instituted a 24-hr emergency replantation service in 1988. A special surgery branch hospital in hand and microsurgery was established in 1991 as the first of its kind in Turkey. Our patient population covers over 10 million people living in a radius of 300 km around Izmir on the Aegean and on the western Anatolian coast who are involved in industrial accidents. The area and population of this region is approximately equal to that of Austria or Hungary. We present a total of 83 patients in our replantation series who were treated between July, 1986, and December, 1990.

MATERIALS AND METHODS

Our series included involvement of 136 extremities from 83 patients. The distribution and level of injuries are indicated in Table 1. Thirty-nine patients suffered total amputations of 71 extremities, while 44 patients suffered incomplete amputations of 65 extremities (Figs. 1–5). Injuries were classified into four types: sharp object (26 patients), local crush (23 patients), severe crush (23 patients), and avulsion (11 patients).

The youngest patient in this series was 2 years old, and the oldest was 55 years old, with the average age being 26 years. Eight females and 75 males were included in our series. Average time prior to hospitalization was estimated to be 4 hr. Indications for replantation were evaluated using the classification established by Meyer and Hubatka.[2] Until recently information was lacking on the proper conditions for amputated extremities during transportation to the hospital. Between 1986 and 1988, we witnessed amputated extremities conveyed to us in plain water, saline solution, or alcohol or wrapped in cloth in a surprisingly high number of cases. In early 1989, we sent a leaflet to 2,500 industrial organizations and the 4,000 doctors associated with them describing the appropriate first aid and cooling actions to be adopted in cases of amputation. From then on, proper conditions were observed. Prompt cooling of the amputated extremity was also applied upon arrival in our hospital. Before the present hospital was established, the average time between the arrival of the patient and initiation of the operation was 1.25 hr, cooling being provided in the interim. In two major operations, intraoperative cooling was maintained due to warm ischemia times of 5.5 and 6 hr. In the 6-hr case, the amputated extremity was lost due to postoperative no-reflow phenomenon.

Surgical Technique

General anesthesia was induced in all but 23 operations. Amputation of the distal phalanx of a single finger was conducted under plexus or digital block. Following induction of anesthesia, the amputated extremity is made aseptic through antiseptic solutions. Affected areas are washed with liberal quantities of gentamicin sulfate saline solution. Then, debridement is performed according to the type of injury and damage. In cases of crush, all necrotic tissues are debrided. In amputations with sharp objects, debridement is kept to a minimum. However, in major amputations, especially middle and distal forearm amputations, muscles in the

From the Hand and Microsurgery Hospital, Kahramanlar, Izmir, Turkey.

This paper was presented at the Eleventh Congress of the International Microsurgical Society, Rhodes, Greece, June 21–26, 1992.

Address reprint requests to Arslan Bora, El ve Mikrocerrahi Hastanesi, 1418 Sok., No:14, 35230 Kahramanlar, Izmir, Turkey.

Received for publication August 4, 1992.

Table 1. Distribution of Injuries.

Level of injury	Number of patients
Arm	1
Proximal forearm	4
Distal forearm	7
Transcarpal	6
Transmetacarpal	3
Foot	2
Finger (total of 113 fingers)	60
Total	83

distal forearm of the amputated extremity are debrided completely. Following debridement, washing with gentamicin sulfate saline solution is maintained for 10 min. Then, the amount of bone to be shortened is calculated. In our series, bone shortening was between 0.5 and 6.0 cm. We prefer to shorten the bones a little more than is absolutely necessary. In consequence, we needed to perform vein grafting in only three patients. In one case, a two-level major arm amputation, a vein graft was placed in the brachial artery. The other two cases were avulsion injuries. Considering the average length of warm ischemia and in order to decrease the actual operative time, we attempted to eliminate the need for vein grafting by aggressive bone shortening. Once the bone had been shortened, vein grafting was used only if the freed vessel ends could not be opposed by the approximator during the anastomotic process. The usual procedure in minor amputations was to anastomose one artery and two veins. In forearm amputations, however, anastomosis of two arteries was the rule. All nerves were primarily sutured. In no case did we need to perform nerve grafting. Bone fixation was accomplished predominantly with Kirschner wires. Cross or longitudinal wires were used in 62 cases, while four others required oblique wires. Thirteen patients underwent osteosynthesis with plates as a means of fixation, and two were treated with an external fixator. A proximal row carpectomy was performed in a single case. Four patients underwent orthrodesis.

Postoperative Follow-Up

Patients received 5,000 units of intravenous heparin during the operation. Postoperatively, they were given

Figure 1. Forty-six-year-old male patient, employed as captain of a day-trip boat. In 1989, he suffered total amputation of his left foot due to entanglement with the rope from the boat. A nurse who was on the beach at the time stopped the bleeding and recovered the amputated foot from the sea. One year after the operation, he is capable of bearing his full weight and standing on one foot. He has resumed his old job as a boat captain.

Figure 2. A 24-year-old female textile engineer had the ring finger of her right hand cleanly amputated at the phalanx lunula distal position by electric scissors. Replantation was performed after her persistent requests. Results 1.5 months postoperatively.

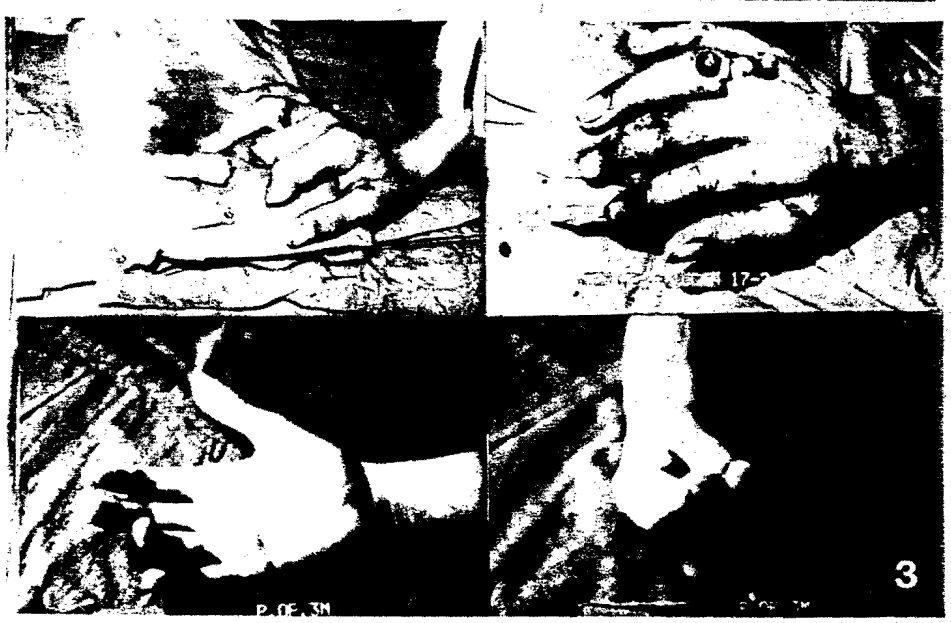

Figure 3. A 17-year-old male patient who suffered amputation of the index and middle fingers of his right hand while working on a machine manufacturing job. He also suffered an incomplete amputation of the ring finger. Results are 3.5 years postoperatively.

5,000 units of heparin subcutaneously twice per day for 10 days as well as 250 ml of 10% low-molecular-weight dextran 40 twice per day for 7 days. All patients were given gentamicin sulfate intramuscularly (80 mg, three times per day for 5 days), and in addition, major cases received intravenous ceftriaxone (1 g, two times per day for 5 days). Temperature, color, turgor, capillary refill, and Doppler examinations were used to monitor the postoperative status of the replanted extremities.

Evaluation

Our follow-up period averaged 35.9 months and ranged from 19 to 65 months. Physical therapy was begun at ~1 month postoperatively depending on the condition of the

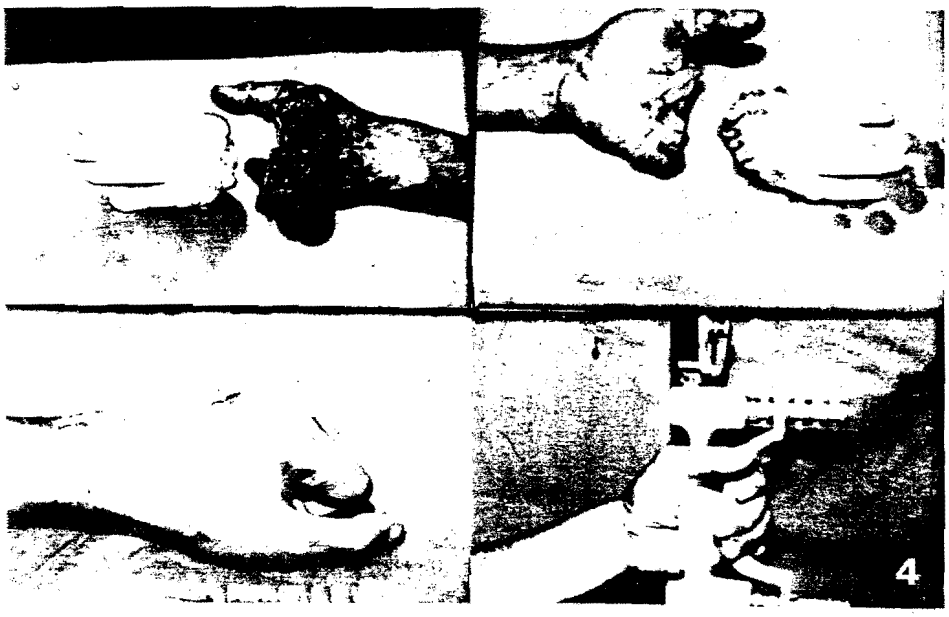

Figure 4. A 23-year-old male patient suffered a transcarpal amputation of his left hand 2 years ago while working in an aluminum frame manufacturing workshop. Postoperative results are 1.5 years after injury.

Figure 5. A 17-year-old patient suffered an amputation of his left forearm at the distal one-third as he was cleaning the textile machinery in his father's factory. Results are 1.5 years after injury. He is satisfied with his hand but has not resumed his previous occupation for fear of a similar accident.

wounds and was continued for 3–18 months. Early postoperative splinting was not performed in any of our cases. Only after a full month was splinting initiated. Intensive hydrotherapy, exercising, and electrotherapy were also used.

Routine electromyography (EMG) was performed in all cases after the postoperative months 3, 6, 12, and 18. Goniometric measurements as well as gripping and pinching abilities were measured and compared to those of the healthy limb. Sensory ability was measured by the two-point discrimination test, the Semmens-Weinstein esthesiometric test,[3] and by the localized deep pressure and light touch tests. The fundamental movements of daily life, as determined by Nakamura and Tamai in Tamai et al.[4] were examined. Patients were questioned regarding whether they were satisfied with the aesthetic appearance and the functional capacity of their extremities, the intolerance to cold (average temperature of Aegean region is 17.5°C, so the majority of patients reported no complaint), and whether they had returned to their previous occupations.

COMPLICATIONS

Reconstructive procedures such as the McGregor flap[5] (seven cases), the dorsal metacarpal flap (one case) and the Atasoy flap[6] (four cases) were performed immediately for necrosis complications. Secondary interventions for tendon, nerve, or bone reconstruction were performed at least 3 months postoperative. Two patients required nerve repair, six underwent bone grafting for pseudoarthrosis, three received skin grafts, and extensor tendon repair and arthrodesis were each performed in a single patient. No cases of early postoperative infection occurred in our series. Late bone infection and pseudoarthrosis were observed in two major cases. Both of these cases of bone union problems were successfully resolved.

RESULTS

In our total series of 83 cases, 112 of 136 replanted extremities were successful, bringing our overall success rate to 82%. Postoperative thromboses and necrosis were observed in 23 of 113 finger amputations, a success rate of 79% for these more minor amputations. In the 23 major amputations, there was only one loss, a success rate, here, of 96%.

Functional evaluations were made using the criteria introduced by Chen et al.[7] Fourteen patients were judged as having very good functional results, and 35 had good, 24 had moderate, and 5 had poor results. We believe that functional results depend on factors such as type of injury, physical therapy, warm ischemia times, and experience of the operating and physical therapy team.

CONCLUSIONS

Although the first successful replantations and revascularizations were performed 30 years ago, our team has had only 6 years of microsurgical experience. In this paper, we have describe our first 3.5 years of replantation cases. The average follow-up was 35.9 months, with a success rate of 82%. We believe that these results are encouraging and speculate that the type of injury and length of warm ischemia have a direct effect on the success and functional results of the replantations.

REFERENCES

1. Gulgonen A: Replantasyonlar. *Dahili ve Cerrahi Acil Hastaliklar*, 24: 380–392, 1979.
2. Meyer VE, Hubatka G: *Replantation Surgery of the Upper Limb. Documenta Geigy*. Basel, Ciba Geigy Limited, 1980, pp 11–13.
3. Levin S, Pearshall G, Ruderman R: Von Frey's method of measuring pressure sensibility in the hand: An engineering analysis of the Weinstein-Semmes pressure aesthesiometer. *J Hand Surg* 3:211–216, 1978.
4. Tamai S, Michon J, Tupper J, Fleming J: Report of subcommittee on replantation. Microsurgical committee. *J Hand Surg* 8:730–732, 1983.
5. McGregor IA, Jackson IT: The groin flap. *Br J Plast Surg* 25:3–16, 1972.
6. Atasoy E, Ioakimidis E, Kasdon ML, Kutz JE, Kleinert HE: Reconstruction of the amputated finger tip with a triangular volar flap. A new surgical procedure. *J Bone Joint Surg* 52A:921–926, 1970.
7. Chen CW, Qian YQ, Yu ZJ: Extremity replantation *World J Surg* 2:513–24, 1978.