Eur J Orthop Surg Traumatol
DOI 10.1007/s00590-009-0557-0

CASE REPORT

# An iatrogenic femoral nerve injury after open reduction and displacement iliac osteotomy for hip dysplasia: a case report

**K. Ertem · Y. Karakoç · A. Cetin · A. Bora**

Received: 19 June 2009 / Accepted: 22 September 2009


**Abstract** In this report, we present a 4-year-old female patient who came to our clinic complaining of symptoms that were then attributed to a right femoral nerve injury, 15 months after open reduction, and innominate osteotomy operations performed at another orthopedic center. The operations were performed using the Smith–Peterson incision technique and led to a neurotmetic femoral nerve injury. In our clinic, we repaired damaged femoral nerve by sural nerve graft using interfascicular technique. After 6 years, she was walking without additional device or hand to stabilize the knee.

**Keywords** Congenital hip dislocation · Peripheral nerve · Femoral nerve injury

## Introduction

The femoral nerve is usually injured as a result of penetrating trauma to the groin or iatrogenically during herniorraphy, saphenous vein ligation, anterior hip exposure, and other proximal tight procedures [ ]. In response to this problem, Smith-Peterson (1917) developed and popularized the anterior approach that is currently used for the reduction of congenitally dislocated hips in ambulatory children and displacement iliac osteotomies for dysplasia [ ]. Tachdjian [ ] emphasized that femoral nerve injury is just as serious a complication in cases of hip dysplasia operated on using the anterior approach. This problem may be caused by stretching or inadvertent division of the femoral nerve when it is mistaken for the psoas tendon during surgery. The use of a nerve stimulator may help to distinguish the femoral nerve from the tendon [ ].

We assessed a 4-year-old female patient who was operated before 15 months for open reduction and innominate osteotomy operations performed using the Smith–Peterson incision technique at another orthopedic center, and presented with the unusual complication of right femoral nerve injury.

## Case report

A 4-year-old female patient came to our clinic complaining of walking difficulties and frequently falling 15 months after open reduction and innominate osteotomy operations performed using the Smith–Peterson incision technique at another orthopedic center (Fig. a, b). A disorder of the right lower extremity, frequent falling, and weakness during ambulation were also noted in the patient's history. The patient had also no history of trauma or neurological deficits. In our clinical examination, she could not extend or stabilize her knee during ambulation. She was walking only by the stabilization of knee with the help of right hand to the extension. Strength and range of motion (ROM) in the

K. Ertem (✉)
Department of Orthopaedics and Traumatology,
Faculty of Medicine, Inonu University, 44315 Malatya, Turkey
e-mail: kertem@inonu.edu.tr

Y. Karakoç
Department of Physiology, Faculty of Medicine,
Inonu University, Malatya, Turkey

A. Cetin
Department of Anatomy, Faculty of Medicine,
Inonu University, Malatya, Turkey

A. Bora
Department of Orthopaedics and Traumatology,
Izmir Ataturk Training and Research Hospital, Izmir, Turkey

Published online: 22 October 2009

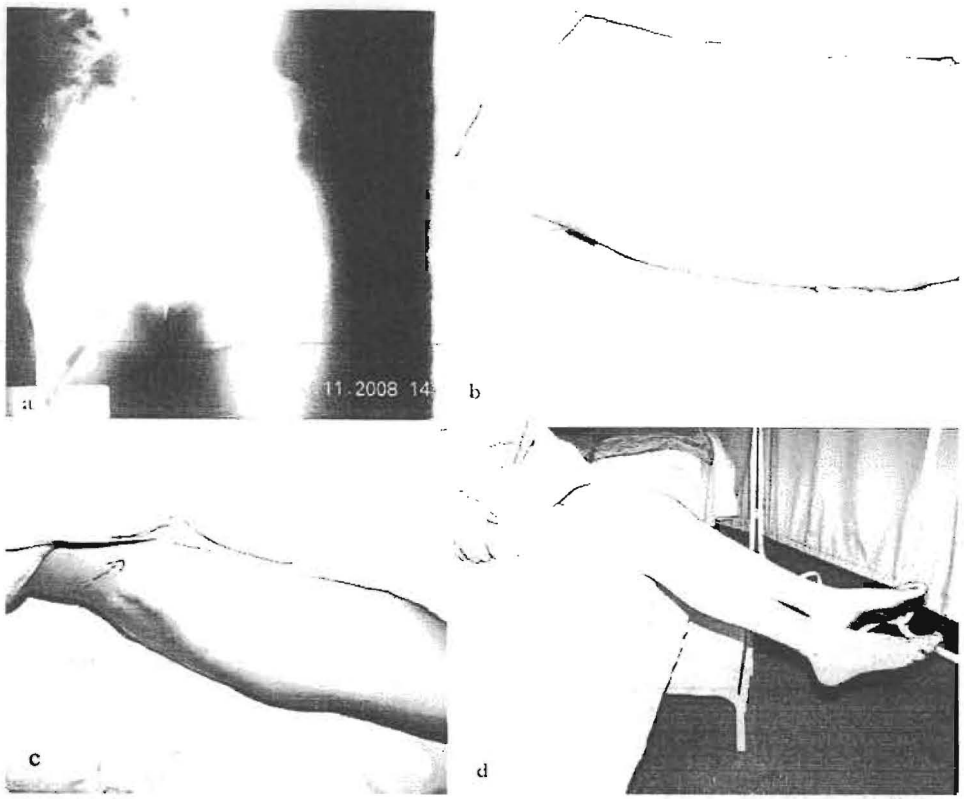


**Fig. 1** **a** Preoperative X-ray image of the pelvis, AP projection. **b** Appearance of the anterior Smith–Peterson incision scar. **c** Appearance of the repaired femoral nerve incision scar. **d** Demonstration of active knee extensions

right hip and foot were similar to the contralateral side. However, right quadriceps strength was 2/5 according to the British Medical Research Council (BMRC) scale. In addition, the right patellar deep tendon reflex (DTR) was absent, and the right thigh was atrophic when compared to the healthy side, at about 5 cm. In electromyographical examination, there was no contraction of the vastus medialis muscle during stimulation of the femoral nerve at the inguinal channel, and motor unit potentials were not detected. The electromyographical examination also revealed a femoral nerve conduction block.

A 5-cm incision running both proximally and distally from the inguinal ligament and parallel to the femoral nerve was performed under general anesthesia (Fig. c). Then, during exploration of the femoral nerve under a surgical microscope, a neurotmetic nerve injury was seen. After exploration of the nerve, two nerve stumps were prepared. The femoral nerve, which innervates the quadriceps muscle, was stimulated at the proximal level by a short bevel needle for plexus anesthesia with injection tube and extension lead connected to a nerve stimulator (Stimuplex A), but we did not detect any contraction in the quadriceps muscle. Neuromatous tissue was resected until normal nerve fascicules were encountered. During neurolysis under the surgical microscope, we did not find any healthy nerve fascicles in the damaged area of the right femoral nerve. Thus, this was evaluated to be a neurotmetic injury [ ]. Neuroma was also verified by pathological assessment of excised tissue.

For the femoral nerve repair, neuroma tissue was excised from the proximal end, and the damaged section of the nerve was prepared by cutting until fascicles appeared at the distal end. After these interventions, a gap was seen about 7 cm in the right femoral nerve. As a result, the sural nerve graft taken from the right leg was attached to the damaged femoral nerve as a four-cable shape using the interfascicular technique.

After this operation, resting in bed was suggested for 2 weeks, and then rehabilitation of the quadriceps muscle was begun using active and passive ROM exercises, transcutaneous electrical nerve stimulation (TENS) and strength-building exercises. The patient was evaluated monthly for the first 6 months, bimonthly for the second 6 months, and then twice per year. Six months after the operation, electrophysiological examination had been performed and periodically repeated for control.

At the 6-year follow-up, the patient had neither gait problems nor the need for a walking-assistance device. She was walking without any difficulty extending or stabilizing the knee during ambulation. The strength of the quadriceps

muscle had reached 4/5 according to the BMRC scale (Fig. d). Both lower extremities had the same extent, but about 6 cm of atrophy remained on the operated side. In this case, persistent atrophy may be attributed to substantially loss of motor end plates because of 15 months delay to come to hospital in order to femoral nerve repair. Remaining of 6 cm difference between two thighs from the pre-operative period showed that atrophic muscle had greatly responded to our surgical intervention of femoral nerve.

The right patellar DTR was normoactive. Pre-operatively, the amplitude of compound muscle action potentials in the right lower extremity, measured by stimulating the femoral nerve, was 0.1 mV compared to 9.9 mV on the left side. This amplitude gradually increased post-operatively, and finally reached to 2.1 mV.

## Discussion

The femoral nerve runs between the psoas and iliacus muscles. It enters the thigh after passing beneath the inguinal ligament, diverges to supply motor input to the quadriceps, and continues as the saphenous nerve [ ]. This nerve is usually damaged as a result of penetrating trauma to the groin or iatrogenically during herniorraphy, saphenous vein ligation, anterior hip exposure, and other proximal tight procedures. If complete neuropathy has occurred with inability to extend or stabilize the knee during ambulation, microsurgical exploration, and repair are recommended [ ].

Recently, the anterior approach has been used in open reconstructions of anterior column and medial wall acetabular fractures [ ]. In addition, Hoppenfeld et al. [ ] recognized the risk of injury to the lateral femoral cutaneous nerve and the femoral nerve. Within the femoral triangle, the femoral nerve lies directly anterior to the hip joint. Since the nerve is well medial to the rectus femoris, it is not in danger unless one strays to the wrong side of the sartorius and the rectus femoris. If the correct plane is not found during deep dissection, it is necessary to locate the femoral pulse by palpation, as the artery lies medially to the nerve in the femoral triangle [ ].

Tachdjian [ ] drew attention to the complications of open reduction and displacement iliac osteotomy for dysplasia of the hips, which include superficial or deep infection, sciatic nerve palsy, femoral nerve injury, wire problems, loss of correction from crushing the bone graft, medial displacement of the distal segment, post-operative stiffness of the hip, avascular necrosis, and resubluxation or redislocation. It has been suggested that femoral nerve injury may occur by stretching or inadvertent division of the femoral nerve when it is mistaken for the psoas tendon during surgery. A nerve stimulator may help to distinguish the nerve from the tendon [ ]. Ganz et al. [ ] and Pogliacomi et al. [ ] described the risk of periacetabular osteotomy-related damage to the sciatic, femoral, or obturator nerves and a major blood vessel [ , ]. Clarke et al. [ ] reported that 1 of 1,054 patients who underwent hip arthroscopy had a transient femoral nerve palsy, which resolved within 6 h [ ]. Natio et al. [ ] reported that the curved periacetabular osteotomy, a newly developed modification of the Bernese periacetabular osteotomy, prevents the outside of the ilium from being exposed and produces curved osteotomy surfaces with the aim of avoiding complications associated with the Bernese periacetabular osteotomy (e.g., motor nerve palsy, heterotopic ossification, and delayed union of the ilium). However, they found that dysesthesias along the distribution of the lateral femoral cutaneous nerve occurred in 27 of 118 patients (128 hips). Symptoms resolved within 1 year in 23 of the 27 patients [ ]. Ganz et al. [ ] found that femoral nerve palsies resolved nonoperatively in 75 patients who underwent periacetabular osteotomies of hip by the Smith–Petersen approach [ ]. Peters et al. [ ] reported three patients with transient femoral nerve palsies out of 73 patients (83 hips) who underwent Bernese periacetabular osteotomies between 1997 and 2003. Two of the patients had complete resolutions of their palsies within the first year, while the third had residual weakness and numbness [ ].

Seddon developed a functional classification describing three types of peripheral nerve injury. The first type is neuropraxia, which describes complete motor paralysis usually with substantial sparing of sensory and sympathetic functions. It is caused by an acute local demyelinating block that occurs with compression injuries. Such conduction blocks persist until the completion of local myelin repair, which restores excitability and conduction of nerve fibers in the injured segment over a period of weeks to months. The second type of nerve injury is axonotmezis that describes a loss of axonal continuity with sparing of the endoneural tubes at the site of the lesion. In these cases, the time required for functional recovery depends on the time required for axonal regeneration and reinnervation of distal targets. The third type of injury is neurotmesis, which describes a total severance of the nerve. Spontaneous regeneration does not occur in these cases; thus microsurgical nerve repair is required [ ]. In our case, right femoral nerve damage was also neurotmesis type nerve injury.

Quadriceps muscle normally stabilizes the knee at the extension during the gait. Since quadriceps muscle is functionally insufficient, subject can walk with the help of hand or additional device [ ]. In our case, stabilization of the knee not using her hand and walking ability without additional device show the improvement of the femoral nerve and quadriceps muscle functions.

In our pre-operative clinical examination, the strength of the patient's right quadriceps muscle was 2/5 according to the BMRC scale. However, there was no activity in the right quadriceps during stimulation of the femoral nerve with a needle electrode. These findings suggest that 2/5 right quadriceps strength can be generated by extensor activity of the tensor fasciae latae. Normally, the tensor fasciae latae helps to extend the knee and maintain upright posture [ ].

As discussed earlier, the majority of iatrogenic nerve injuries resulting from Smith–Peterson incisions during hip reconstructions were previously reported to be neuropraxia or axonotmesis types. However, we discovered a neurotmetic injury of the femoral nerve 15 months after one of these operations was performed. A 7-cm defect in the femoral nerve was repaired with 7-cm cable grafts. After 6 years, our clinical and laboratory findings revealed neither a gait problem nor the need for a walking assistance device. The patient could walk without limping and had no difficulty extending or stabilizing the knee during ambulation. The strength of the quadriceps muscle had increased to 4/5, and the amplitude of compound muscle action potentials of the right lower extremity had increased to 2.1 mV.

In conclusion, our results show that a neurotmetic femoral nerve injury can be operated successfully even if the damage occurred 15 months ago. Surgeons should be cognizant of the possibility of iatrogenic nerve injuries when using the Smith–Peterson incision technique for open reduction and innominate osteotomies.

**Conflict of interest statement** No funds were received in support of this study.

## References

1. Cantarella V (1999) Bones and muscles:an illustrated anatomy. Wolf Fly Press, New York
2. Clarke MT, Arora A, Villar RN (2003) Hip arthroscopy: complications in 1054 cases. Clin Orthop Relat Res 406:84–88
3. Ganz R, Klaue K, Vinh TS et al (1988) A new periacetabular osteotomy for the treatment of hip dysplasias. Technique and preliminary results. Clin Orthop Relat Res 232:26–36
4. Gelberman RH (1991) Operative nerve repair and recontsruction, vol 1. J.B. Lippicott Company, Philadelphia, pp 489–504
5. Hoppenfeld S, Winters R, Hoeltzel LE (1984) The hip. In: Surgical exposures in orthopedics. J.B. Lippincott Company, Philadelphia, pp 301–356
6. Lundborg G, Danielsen N (1991) Injury, degeneration and regeneration. In: Gelberman RH (ed) Operative nerve repair and recontsruction, vol 1. J.B. Lippicott Company, Philadelphia, pp 109–131
7. Naito M, Shiramizu K, Akiyoshi Y et al (2005) Curved periacetabular osteotomy for treatment of dysplastic hip. Clin Orthop Relat Res 433:129–135
8. Owens PW (2007) Complication of nerve injury and repair. In: Cohn SM (ed) Complications in surgery and trauma. Informa Healthcare, New York, pp 505–513
9. Pellegrini VD, Evarts CM (1990) Surgical approaches to the hip joint. In: Evarts CM (ed) Surgery of musculoskeletal system, vol 3, 2nd edn. Churchill Livingstone, New York, pp 2735–2756
10. Peters CL, Erickson JA, Hines JL (2006) Early results of the bernese periacetabular osteotomy: the learning curve at an academic medical center. J Bone Joint Surg Am 88(9):1920–1926
11. Pogliacomi F, Stark A, Vaienti E et al (2003) Periacetabular osteotomy of the hip: the ilioinguinal approach. Acta Biomed 74(1):38–46
12. Tachdjian MO (1990) Congenital dysplasia of the hip. In: Tachdjian pediatric orthopedics, 2nd edn,vol. 1. W.B. Saunders, Philadelphia, pp 297–549